JUVENILE (IMMUNO) DEVELOPMENTAL STUDY IN GÖTTINGEN MINIPIGS®

TNO triskelion bv

THE INTEREST IN JUVENILE SAFETY TESTING IS RAPIDLY GROWING. ALTHOUGH THE RAT IS THE FIRST SPECIES OF CHOICE IN THIS KIND OF RESEARCH, FOR LOGISTIC AND/OR SCIENTIFIC REASONS THE RAT MAY NOT ALWAYS BE THE APPROPRIATE SPECIES. FOR THOSE CASES, THE MINIPIG CAN BE A GOOD ALTERNATIVE.

APM Wolterbeek[1]*, GJD van Mierlo[1], MJ Appel[1], JP Bruijntjes[1], DH Waalkens-Berendsen[1], RA Woutersen[2], CJ Snel[1], CF Kuper[2], AH Penninks[1]

* P: +31 88 866 50 53
M: +31 6 130 902 11
E: Andre.wolterbeek@tno.triskelion.nl

[1] TNO Triskelion BV, P.O. Box 844, 3700 AV, Zeist, The Netherlands
[2] TNO, P.O. Box 360, 3700 AJ, Zeist, The Netherlands TNO

To improve the usefulness of the minipig in juvenile (safety) testing, the basic knowledge about the development of main organ systems needs to be extended.
The aim of the present study was to gain more knowledge about
1) physical and sensory development of the minipig (developmental landmarks),
2) haematological and clinical chemistry parameters during development,
3) immunological parameters during development,
4) histology of main organs during development.

STUDY OUTLINE

Five pregnant sows and 12 male and 12 female minipigs of 2, 3, and 6 months of age were obtained from Ellegaard Göttingen Minipig A/S. Following birth, the physical and sensory development of the piglets was followed. At an age of 2, 7, 13, 27 days and 2, 3 and 6 months blood was collected of 4 male and 4 female pigs for hematology, clinical chemistry and immunological parameters (lymphocyte subset analysis and natural killer (NK) cell activity) and a series of organs and tissues was collected to study age-related and developmental histology and background histopathology.

Figure 1. A minipig sow with piglets. At birth piglets are relatively mature regarding physical and sensory development.

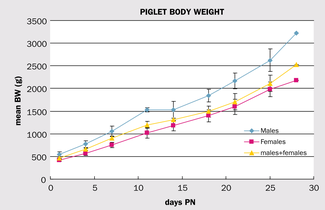

Figure 2. Weight of the piglets during lactation.

RESULT

At birth the minipig is relatively mature regarding general physical and sensory parameters (e.g. eye opening, hair growth and teeth eruption) (Figure 1). Growth of the male and female piglets during the lactation phase is shown in Figure 2. Quantitative and qualitative (functional) immunological endpoints were overall successfully implemented in these minipigs (Figure 3 and 4).

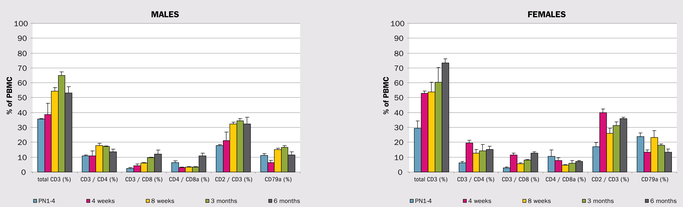

Figure 3. Lymphocyte subset analysis. PBMC isolated from blood of male and female minipigs from several ages was performed by flow cytometric analysis. The relative cell numbers (% of PBMC) are depicted for the different cell populations after correction for isotype control stainings. Mean + SEM for each group are depicted.

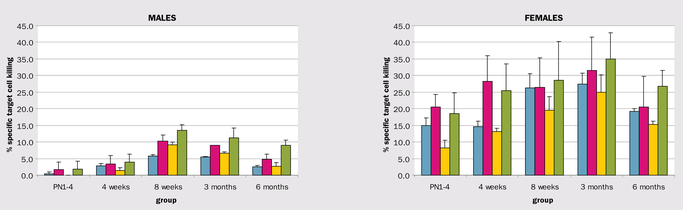

Figure 4. Natural killer cell activity assay. PBMC were incubated overnight (37°C) with CFSE labeled NK sensitive K562 target cells in the presence or absence of rhIL2 at an Effector-to-Target ratio of 100:1 or 50:1. After 18 hours of incubation propidium iodide was added and percentage of target cell killing was analyzed by flow cytometry. Mean + SEM for each group are depicted.

Some organs were (almost) fully developed at birth, while others showed distinct postnatal development (thymus, bone marrow, spleen, lymph nodes, Peyer's patches, bronchus associated lymphoid tissues, pancreas, liver, adrenals, kidneys, male and female reproductive system, skin and brain) (Table 1).

CONCLUSIONS

Although the minipig is born relatively mature regarding general physical and sensory development, the juvenile minipig might be a suitable model to evaluate the effects of potential toxic compounds on the developmental of the nervous-, reproductive and immune systems. However, as for other species, more basic information is needed on juvenile development of the minipig.

Table 1. Age-related and developmental histology in Göttingen minipigs® (1 day – 6 months).

CARDIOVASCULAR SYSTEM	**UROGENITAL TRACT SYSTEM**
Heart	Kidneys
	Urinary bladder
HEMOPOIETIC SYSTEM	**MALE GENITAL SYSTEM**
Thymus	Testes
Bone marrow (sternum)	Epididymides
Spleen	Prostate
Lymph nodes	Seminal vesicles/coagulation glands
Peyer's patches	**FEMALE GENITAL TRACT**
Bronchus associated lymphoid tissues (BALT)	Uterus
RESPIRATORY TRACT AND LUNGS	Vagina
Lungs	Ovaries and oviduct
PANCREAS, LIVER AND GALLBLADDER	**NERVOUS SYSTEM**
Pancreas	Sciatic (peripheral) nerve
Liver	Brain
Gall bladder	**SOFT TISSUE**
ENDOCRINE SYSTEM	Mamma
Adrenals	Skin

Some organs were almost fully developed at birth, while other organs show distinct postnatal development (pink areas).

TNO innovation for life

This study was sponsored by Ellegaard Göttingen Minipig A/S.

Ellegaard