

# Göttingen Minipigs MR and CT Imaging Atlas

A comprehensive imaging atlas presenting detailed information about the physiology of Göttingen Minipigs has been made available for anyone interested in the anatomical evolution of Göttingen Minipigs. This documentation enables a unique opportunity to follow the development of all organs over time and obtain new data.

The images are made from high-resolution CT- and MRI-scans and the atlas covers a wide range of information based on the scans (see page 2). With these, a user-friendly virtual minipig can be created using freely available software, and organ development analyses can be performed.

## Why the imaging atlas is important

The imaging atlas fully supports all three parameters of the 3R principles, which contribute with important steps in the development of safer and more effective medicines:

- *Replacement*; as the access to and use of the imaging atlas can fully replace the use of new animals in similar studies
- *Reduction*; as the use of the imaging atlas can fully or partly reduce the number of animals used to obtain the same amount of scientific information
- *Refinement*; as reducing animal distress is a direct result of a reduced need for operational studies, since knowledge can be obtained through the images, which also supports the definition of age and development-stage

## Access to the images

You can gain access to the database with CT- and MRI-scan files free of charge after signing an MTA. The files may be used for non-commercial, internal and/or knowledge building purposes within your organization.

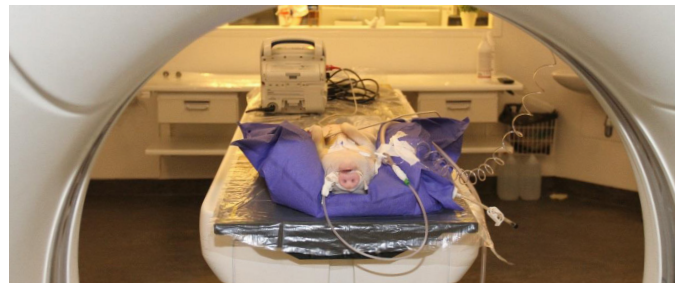Are you interested?

Contact us on [ellegaard@minipigs.dk](mailto:ellegaard@minipigs.dk)

## Background and usability

A total of 12 Göttingen Minipigs were scanned at different ages to follow the anatomical development from the age of 2 to 24 months:

- Four females were scanned repeatedly, at the ages 2-3 months, 4-5 months, 6-7 months and 12-13 months
- Two females and two males at the age of 1 year
- Four females at the age of 2 years



**Picture 2**

Setup at CT scanner with anaesthetized Göttingen Minipigs connected to ventilator and monitor.

“ Throughout the years, we have received many diverse requests from researchers planning experiments with Göttingen Minipigs, e.g. the size of the eyeballs at different ages, the development of the teeth, the size and location of certain organs, arteries, and veins.

This atlas makes it possible to study the anatomy and the development of growing organs, the vascular system and bone structures, and makes it easier to choose the right model for each research set-up. Likewise, pre-study considerations, such as age, growth during study period, equipment and probe sizes etc., can be solved beforehand and thereby reduces the use of pilot animals in compliance with the 3R principles.

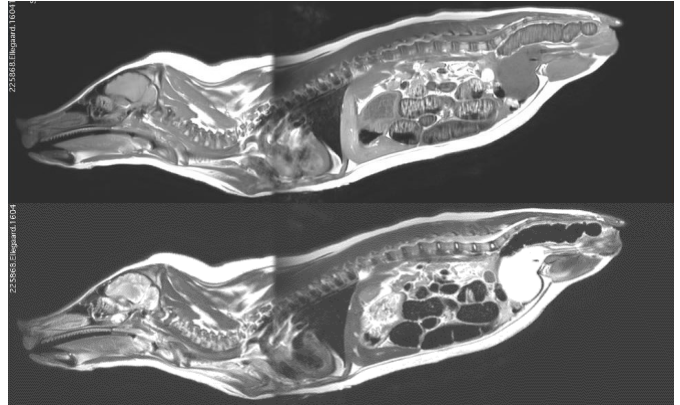
Sigríður Olga Magnúsdóttir  
Aalborg University Hospital | Denmark

### The value of MRI-scans

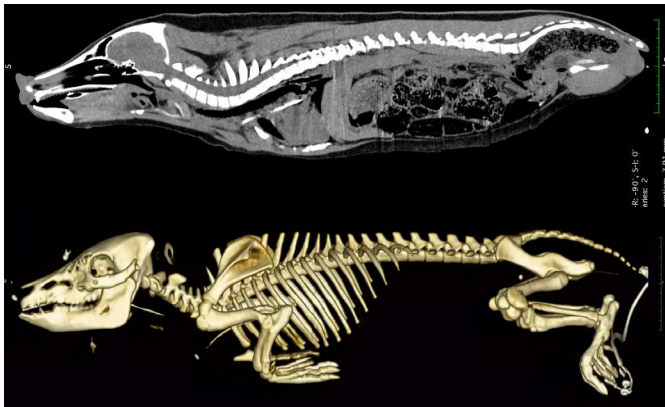MRI-scans illustrate higher detail in soft tissues and has the ability to change the contrast of the images, which highlight different types of tissue. For example, the signal intensity for fluids is low in T1 weighted images, but high in T2 weighted images. Based on this, most soft tissue structures can be differentiated through either inherent contrast or comparison between the two. The high resolution images depict and enable most organs for segmentation, and sequential scan sets enable a time-evolution curve of all organs.

### The value of CT-scans

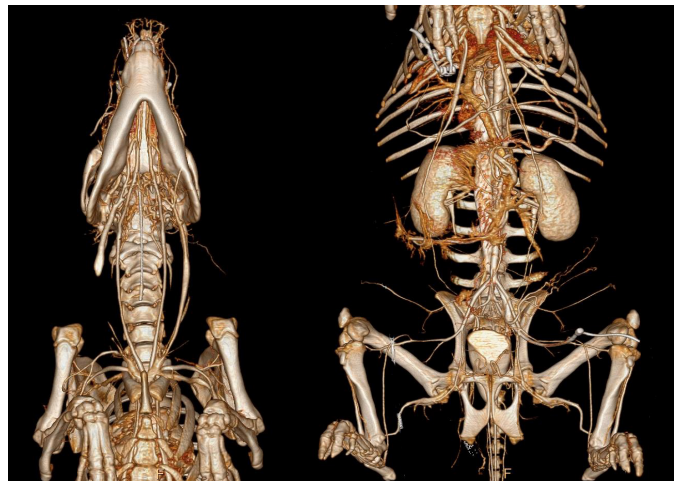
CT-scans are great for imaging the bone structure, good for soft tissue differentiation (particularly with intravenous contrast), and generally provides higher imaging resolution with less motion artifact. The x-ray based CT-scans outline high dense materials very clearly, when segmenting bone structures based on the CT-scans. The cardiovascular system becomes visible through contrast agent administration, and can be segmented with great results.



**Picture 3**  
MRI-scans showing sagittal T1 weighted (top) and sagittal T2 weighted (bottom).



**Picture 4**  
Full body CT scan of Göttingen Minipigs and CT scan of Göttingen Minipigs showing segmented bone structure.



**Picture 5**  
CT scan showing frontal and distal segmentation of bone structure and cardiovascular system.